

EARLY DETECTION OF HEAD AND NECK CANCER

Bethan Evans, MBChB

INTRODUCTION

Head and neck cancers are rare with only 8,000 cases and 2,700 deaths *per annum* in England and Wales.⁽¹⁾ It is estimated that a general practitioner (GP) will see one case every six years.⁽²⁾ The banner of head and neck cancer is very broad incorporating over 30 specific sites and with such diverse anatomy and histology, each cancer presents with a separate set of clinical features. It has been highlighted that the most significant prognostic factor in survival is the stage at which patients present,⁽²⁾ and that earlier diagnosis relates to a better outcome. It is therefore crucial that all healthcare professionals are able to recognise the signs and symptoms of head and neck cancer. This article was written in response to the recent audit on head and neck cancer in Lancaster (see page 259) and seeks to give a simple refresher on the signs and symptoms that may indicate head and neck cancer and therefore require urgent referral.

RISK FACTORS

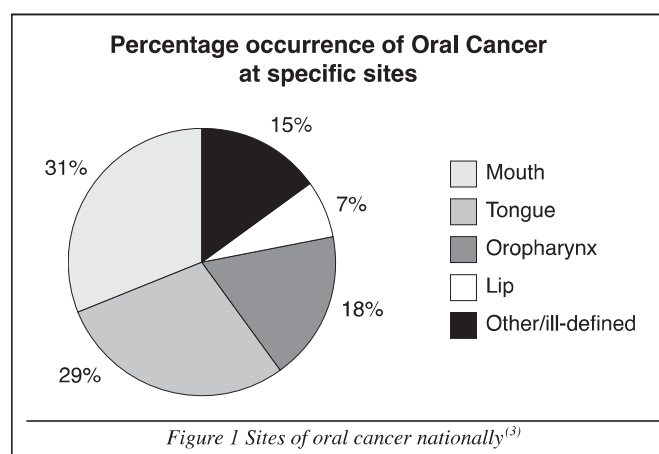
Head and neck cancers have a strong association with certain risk factors and therefore suspicion is increased considerably with the following:

- **Smoking** increases risk of head and neck cancer by ten times that of non-smokers. Risk of developing head and neck cancer is increased by the intensity at which people smoke and is increased further by pipe smoking and chewing tobacco, whilst cessation from smoking for ten years reduces risk to that of non-smokers.
- **High alcohol consumption**, such as 12 units a day, will increase risk of mouth and pharynx cancer by six times; once again the risk is dose dependent.
- **Poor diet** is also held responsible for increased risk of head and neck cancers as a Mediterranean diet of fruit and vegetables, especially tomatoes and fish oils, has been shown to reduce the risk.⁽¹⁾

There is a synergistic effect of alcohol and smoking such that heavy drinkers and heavy smokers have 35 times the risk of developing head and neck cancer than non-drinkers and non-smokers.⁽²⁾

ORAL CANCER

These are the most common of the head and neck cancers, comprised mainly of squamous cell carcinoma (SCC) of the oral epithelium (see figure 1) and are more common in men. Incidence is increasing and is more common in people of South Asian background.



Symptoms include:

- white/red patch on gums/tongue/mouth lining
- persistent sore/lump on lip or mouth
- painful or painless neck lump
- bleeding or numbness in mouth

LARYNGEAL CANCER

Laryngeal cancer is mainly SCC, the second most common cancer of the head and neck and is much more common in males.

Symptoms include:

- chronic hoarseness
- dysphagia
- neck lump
- sore throat
- earache
- persistent cough

HOARSENESS

Common causes of voice change in adults include:

- upper respiratory tract infections
- tumours of vocal cord or larynx – benign or malignant
- bronchial carcinoma
- neurological vocal cord paralysis
- inflammatory – bacterial, viral, TB, allergic, gastro-oesophageal reflux disease
- thyroid surgery

PHARYNGEAL CANCER

Pharyngeal cancers are not common and have poor survival rates, with five-year survival at less than 5%. They include malignancy in three sites: oropharynx (tonsils, base of tongue and soft palate), hypopharynx and nasopharynx.

1. *Oropharyngeal cancer* may present with a persistent sore throat, mouth or throat lump or otalgia. Fifty percent occurs in the tonsils and faucial pillars.
2. *Hypopharyngeal cancer* may present with dysphagia, otalgia and hoarseness.
3. *Nasopharyngeal cancer* will most likely present with a neck lump, nasal obstruction, deafness or post-nasal discharge.

THYROID CANCER

Thyroid cancer has excellent survival rates and is usually found in women of reproductive age. It is very rare but is present in 10% of all patients referred with a solitary thyroid nodule and normal thyroid hormones.

Presentation varies with more than 60% as a single thyroid nodule, 10% as a multinodular swelling, 10% as cervical lymphadenopathy and 10% as distant metastasis.⁽⁴⁾

There are different kinds separated by histology; papillary and follicular adenocarcinoma and medullary cancer. The latter has a familial trend and can be associated with other endocrine malignancies.⁽²⁾ Other risk factors include irradiation exposure.

Thyroid cancer in the elderly is usually one of two kinds; thyroid lymphoma or anaplastic thyroid cancer. The latter has a poor prognosis.

Symptoms of thyroid cancer:

- neck lump
- neck pain sometimes radiating to the ears
- hoarseness
- dysphagia
- difficulty breathing
- persistent cough
- enlarged lymph glands in the neck

DYSPHAGIA

A feeling of something in the throat – usually affects swallowing of liquids and/or solids

- Investigate fully all persistent dysphasia with endoscopy, even with a normal Barium swallow
- Acute dysphagia is usually inflammatory
- Be especially suspicious of neoplasm if associated with:
 - weight loss
 - hoarse voice
 - earache
 - neck mass
 - respiratory difficulty
 - regurgitation

MAXILLARY ANTRUM CANCER

The symptoms of maxillary antrum cancer are related to the anatomy on which a growing tumour affects by compression:

Ocular

- proptosis
- epiphora
- diplopia (double vision)

Nasal

- discharge (bloody and offensive)
- obstruction
- anosmia

Mouth

- loose teeth/ill-fitting dentures
- palatal swelling

Face

- swelling
- paraesthesia

Neck

- metastatic neck lymph nodes

OTHER CANCERS OF HEAD AND NECK

Seventeen percent of head and neck cancers are made up of the following and are very rare:

- salivary glands and other glands
- nasal cavity
- middle ear
- accessory sinuses
- cancers/sarcomas of facial bones
- peripheral nerves
- connective and soft tissue
- bone, eg skull base cancer

NECK LUMPS

Lumps of the neck are a common presentation and 80% of neck lumps are inflammatory. In a patient over 40 years of age, a lateral neck mass is malignant until proven otherwise.⁽⁴⁾

The differential diagnosis of neck lumps (see table 1) depends upon the anatomical position in the neck and clinical features of the lump.⁽⁴⁾

Management includes a thorough history and examination of the head and neck, chest and breasts and then investigations as appropriate. If malignancy is suspected, urgent ultrasound with or without fine needle aspiration would be the most appropriate initial investigation.

Midline neck lumps

- thyroglossal duct cysts
- skin lesions and subcutaneous lesions
- lymph nodes
- dermoid cysts

Thyroid masses

- cysts
- adenocarcinoma
- Hashimoto's thyroiditis

Lateral neck lumps

Skin and subcutaneous lesions

- epidermoid/dermoid/teratoid cysts
- lipoma

Developmental masses

- lymphangiomas
- cystic hygromas
- branchial cysts

Lymph nodes

- infectious
- inflammatory
- neoplastic
- metastatic lymph nodes
- lymphomas

Neurogenic tumours

Vascular tumours

- carotid body tumours

Salivary glands

Clinical features of malignant lymph nodes

- hard
- fixed
- irregular outline
- usually pain free
- singular or multiple

Table 1 Differential diagnosis of neck lumps

CONCLUSION

Cancers of the head and neck are complex and present with a large range of symptoms, and their rarity provides healthcare professionals with added difficulty in diagnosis. The National Institute for Clinical Excellence (NICE) has produced a set of symptoms that warrant urgent two-week referrals (see figure 2).

The two-week wait proforma has been shown to increase the pick-up rate of head and neck cancer but produces a low positive predictive value. Many of the patients referred urgently will not have cancer and perhaps this is the balance we have to accept. The conundrum being the more suspected cancers we refer urgently, the greater the burden to the resources available.

Common non-malignant conditions that are referred include lichen planus, chronic hyperplastic candidiasis, frictional keratosis, recurrent oral ulceration, etc. These high referral rates have led to increased waiting times for patients under a routine referral.⁽⁵⁾

- Ulceration of oral mucosa > 3 weeks
- Oral swellings > 3 weeks
- Red or red and white patches on oral muosa
- Dysphagia > 3 weeks
- Hoarseness > 6 weeks
- Unilateral nasal obstruction especially with purulent discharge
- Unexplained tooth mobility not associated with periodontal disease
- Unresolving neck mass > 3 weeks
- Cranial neuropathy
- Orbital masses

Figure 2 NICE guidelines on urgent referral for head and neck cancer⁽²⁾

In summary, the awareness of clinical features of cancers in the head and neck is imperative to early detection, referral and therefore survival. This article was written to increase awareness and education of all health professionals in the Morecambe Bay area in an effort to increase the detection of head and neck cancers and reduce the number of benign conditions referred under the two-week wait proforma.

REFERENCES

1. Scottish Intercollegiate Guidelines Network. Diagnosis and management of head and neck cancer. A national clinical guideline. October 2006
Available at: <http://www.sign.ac.uk/pdf/sign90.pdf>
2. National Institute for Clinical Excellence. Guidance on cancer services. Improving outcomes in head and neck cancers – The Manual. November 2004. Available at: http://www.nice.org.uk/nicemedia/pdf/csgnhn_themanual.pdf
3. Cancer Research UK. Oral cancer at a glance. (Cited March 2008; updated 19 July 2008) Available at: <http://info.cancerresearchuk.org/cancerandresearch/cancers/oral/>
4. Simo R, Leslie A. Differential diagnosis and management of neck lumps. *Surgery* 2006;24(9):312
5. Singh P, Warnakulasuriya S. The two-week wait cancer initiative on oral cancer; the predictive value of urgent referrals to an oral medicine unit. *Br Dent J* 2006;201(11):717-20