

MEDICAL MANAGEMENT OF AN INTERSTITIAL ECTOPIC PREGNANCY

S Vitthala, MRCOG; S Rao, MRCOG;
G Busby, MRCOG; V Sharan, FRCOG

INTRODUCTION

Interstitial ectopic pregnancy refers to an ectopic pregnancy that has implanted in the interstitial portion of the fallopian tube. It remains the rarest form of tubal gestation and accounts for approximately 2-4% of all ectopic pregnancies and one of every 2500-5000 live births⁽¹⁾. Its unique anatomic location commonly leads to a delay in diagnosis and treatment. It tends to rupture at a more advanced gestation leading to profound haemorrhage. The reported maternal mortality has remained high in the range of 2-2.5%, in contrast to 0.14% for tubal ectopic pregnancies⁽²⁾. We report a case of interstitial ectopic pregnancy successfully treated with methotrexate.

CASE REPORT

A 27-year-old woman (gravida 3 para 2) presented to the hospital with just over six weeks of amenorrhoea and a history of gradual onset lower abdominal pain and brownish vaginal discharge. Initial assessment revealed a positive urinary pregnancy test. The patient's vital signs were stable, without orthostatic blood pressure changes or tachycardia. There was no tenderness on abdominal palpation and the pelvic examination revealed normal cervix with minimal blood-stained discharge in the vagina. The adnexa were non-tender and free of abnormal masses. The ultrasound scan revealed empty uterine cavity and normal ovaries. The initial β hCG (human chorionic gonadotrophin) was 199 IU/l. The subsequent serial β hCGs were 312 IU/l, 635 IU/l, 823 IU/l, and 1185 IU/l on days 3, 5, 7 and 9 respectively. The ectopic pregnancy was suspected due to the suboptimal rise in the β hCG and no intrauterine gestation sac visible on the scan at this stage. The patient was stable and very keen to avoid surgery and was only persuaded of the need for laparoscopy after long discussion. Laparoscopy revealed a cornual ectopic pregnancy on the right adnexa; the rest of the pelvis looked normal in appearance (figure 1).

As there was a high risk of bleeding by surgical resection of the cornual pregnancy, sometimes necessitating a hysterectomy, a decision was made to treat her with methotrexate, without attempting surgical excision. Intramuscular methotrexate (50 mg/m²) was administered after the normal baseline full blood count, renal and liver function tests were normal. She was allowed to go home on the following day with strict advice to return to the hospital if she developed the symptoms of rupture (abdominal pain, dizziness or fainting). The β hCG levels for days 4 and 7 were 1800 IU/l and 1320 IU/l, respectively, after the treatment and steadily declined to less than 25 IU/l in 28 days. At six weeks post-treatment the β hCG levels were normal (< 5 IU/l).

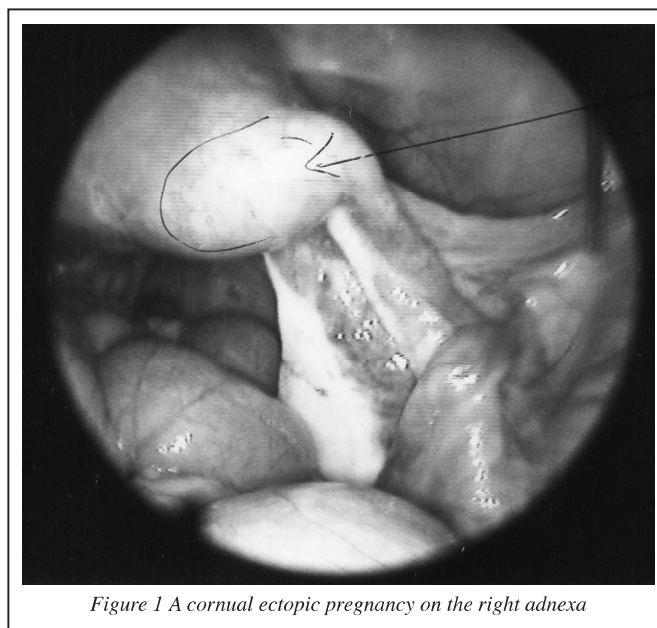


Figure 1 A cornual ectopic pregnancy on the right adnexa

DISCUSSION

Interstitial/cornual pregnancy is a rare form of ectopic pregnancy with an incidence of 1 in 2500-5000 live births; only 2-4% of ectopic pregnancies develop in the isthmus or cornual region of the uterus^(1,2). In interstitial pregnancy, the fertilized ovum implants within the segment of the fallopian tube that penetrates the uterine wall distal to the junction of the endosalpinx and endometrium.

It is important to have a high index of suspicion for ectopic pregnancy since ectopic pregnancy symptoms can be subtle or misleading. Identification of an intrauterine pregnancy with an ultrasound examination is very helpful to exclude ectopic pregnancy. Early blood levels of β hCG normally increase at a certain rate with a normal intrauterine pregnancy and often there is a suboptimal rise of β hCG titers noticed in ectopic pregnancies (abnormally growing intrauterine pregnancy).

Diagnosis of an ectopic pregnancy is challenging since there are neither definitive ectopic pregnancy symptoms nor definitive signs of an ectopic interstitial ectopic pregnancy⁽³⁾. The proximal portion of the fallopian tube is surrounded by the muscular wall of the uterus. Because of the greater distensibility of the myometrium covering the interstitial portion of the tube, the pregnancy is allowed to proceed to a more advanced stage before it ruptures, and because the implantation site is located between the uterine and ovarian arteries, the haemorrhage may be massive and life threatening. The amount of bleeding is from 2.5 to 5 times greater than that in other varieties of ectopic pregnancies and likely to result in a catastrophic haemorrhage and death^(2,4).

Signs and symptoms are non-specific, resembling those of other tubal pregnancies. In our case characteristic sonographic features, like empty uterine cavity, eccentrically located or very lateral gestational sac, thin or incomplete myometrial mantle covering the gestational sac, demonstration of the myometrium between sac and uterine cavity and no gestational sac visible above the level of the internal os in the longitudinal plane of the uterus^(5,6), were absent. Other possible methods of diagnostic importance include magnetic resonance imaging (MRI), useful for the specific diagnoses of the rare forms of ectopic pregnancy, especially when ultrasonographic findings are inconclusive or equivocal. This provides an accurate diagnosis of interstitial/cornual pregnancy as it allows assessment of the tissue located between a mass and the outer surface of the uterus^(7,8,9). Laparoscopy offers an alternative to MRI when ultrasonography fails to confirm the diagnosis of interstitial/cornual pregnancy. It allows direct visualisation of the uterus and concomitant conservative management of the identified ectopic pregnancy.

The management options depend on the timing of the diagnosis, extent of trauma that has occurred in the uterine wall and the patient's desire for maintenance of fertility. The classic treatment of cornual pregnancy is surgical, either cornual resection or simple rupture repair of the lesion. Hysterectomy remains necessary in almost 50% of cases⁽¹⁾; after cornual resection there is a risk of uterine rupture on future gestations during advanced pregnancy or labour. This may result in infertility after the operation. A number of conservative approaches have been introduced⁽²⁾, such as expectant follow-up with serial sonography, systemic methotrexate administration, local injection of chemotherapeutic agents into the gestational sac, hysteroscopic removal and, more recently, laparoscopic resection^(2,10,11,12,13). These procedures have replaced conventional surgical interventions in most cases, and they can also be successfully applied to interstitial/cornual pregnancy. The overall success rate of local, systemic, and combined methotrexate therapy is around 83%⁽²⁾. Early diagnosis made before the interstitial/cornual pregnancy ruptures is necessary for the conservative options.

Systemic methotrexate administration is a well-recognised form of treatment for unruptured ectopic pregnancies with success rates reported between 85% and 96%⁽¹⁴⁾. One of the main advantages of conservative management seems to be the preservation of future fertility⁽¹⁵⁾.

Methotrexate can be used to treat ectopic pregnancy when the following criteria are met:

- hemodynamic stability
- β hCG <3000 IU/l
- transvaginal ultrasound – adnexal mass <3cm with no fetal heart
- case to be discussed or reviewed by the consultant
- methotrexate information leaflet given to the patient
- patient fully understands and will be compliant with regular follow-up until β hCG returns to normal

Methotrexate use is contraindicated in the following circumstances:

- breastfeeding
- peptic ulcers

- active lung disease
- liver, kidney or bone marrow disorders

Patients are informed regarding the increased abdominal pain because methotrexate destroys the placental tissue⁽¹⁶⁾ – the tissue sloughs, separates from the tube and leads to localised bleeding.

The β hCG levels go up in the first few days because of placental tissue breakdown and release of β hCG into the circulation in the first three days, and they are expected to fall at least 15% between days 4 and 7. More than one course of methotrexate is needed for 1 in 4 patients and up to 1 in 3 patients will require follow-up laparoscopy. Continued increases in β hCG levels after one week of initial therapy necessitate the repeat dose of methotrexate. β hCG levels are monitored until they are negative (<5 IU/l). Increased abdominal pain, unstable vital signs consistent with significant internal bleeding and persistently increasing β hCG levels after four to seven days post-treatment all suggest treatment failure.

Patients need to be carefully monitored for signs of tubal site rupture. If tubal rupture occurs, pain markedly increases and vital signs become unstable; emergency surgery is required in these situations.

CONCLUSION

The combination of ultrasound and diagnostic laparoscopy was instrumental in making the diagnosis of an intramural ectopic pregnancy in this patient. Treatment of intramural pregnancy depends on when it is diagnosed; if intramural pregnancy is discovered before rupture, conservative treatment with systemic injection of methotrexate could be considered, which would aid in maintaining fertility.

REFERENCES

1. Rock JA, Thompson JD. *Telinde's Operative Gynaecology*. 8th Ed. Philadelphia: Lippincott-Raven; 1997
2. Lau S, Tulandi T. Conservative medical and surgical management of interstitial ectopic pregnancy. *Fertil Steril* 1999;72(2):207-15
3. Cartwright PS. Ectopic pregnancy. IN Jones HW, Wentz AC, Burnett LS, editors. *Novak's textbook of gynecology*. 11th Ed. Baltimore: Williams & Wilkins; 1988. pp 479-506
4. Felmus LB, Pedowitz P. Interstitial pregnancy: a survey of 45 cases. *Am J Obstet Gynecol* 1953;66(6):1271-9
5. Timor-Tritsch IE, Monteagudo A, Matera C, Veit CR. Sonographic evolution of cornual pregnancies treated without surgery. *Obstet Gynecol* 1992;79(6):1044-9
6. de Boer CN, van Dongen PW, Willemsen WN, Klapwijk CW. Ultrasound diagnosis of interstitial pregnancy. *Eur J Obstet Gynecol Reprod Biol* 1992;47(2):164-6
7. Lee C, Fogarty K, Jolley A. Magnetic resonance imaging in the diagnosis of suspected cornual pregnancy. A case report. *J Reprod Med* 1995;40(6):474-6

8. Hamada S, Naka O, Moride N, Higuchi K, Takahashi H. Ultrasonography and magnetic resonance imaging findings in a patient with an unruptured interstitial pregnancy. *Eur J Obstet Gynecol Reprod Biol* 1997;73(2):197-201
9. Takeuchi K, Yamada T, Oomori S, Ideta K, Moriyama T, Maruo T. (1999). Comparison of magnetic resonance imaging and ultrasonography in the early diagnosis of interstitial pregnancy. *J Reprod Med* 1999;44(3):265-8
10. Lurie S. The history of the diagnosis and treatment of ectopic pregnancy: a medical adventure. *Eur J Obstet Gynecol Reprod Biol* 1992;43(1):1-7
11. Gleischer N, Karande V, Rabin D. Laparoscopic removal of twin cornual pregnancy by injection under ultrasound control. *Lancet* 1994;1:1161-2
12. Chandra D, Koenigsberg M, Romney SL, Koren Z, Schulman H. Unruptured interstitial pregnancy: diagnosis and treatment. *Obstet Gynecol* 1978;52(5):612-15
13. Sanz LE, Verosko J. Hysteroscopic management of cornual ectopic pregnancy. *Obstet Gynecol* 2002; 99 (5 Pt 2):941-4
14. Henry MA, Gentry WL. Single injection of methotrexate for treatment of ectopic pregnancies. *Am J Obstet Gynecol* 1994;171(6):1584-7
15. Glock JL, Johnson JV, Brumsted JR. Efficacy and safety of single dose systemic methotrexate in the treatment of ectopic pregnancy. *Fertil Steril* 1994;62(4):716-21
16. Keriakos R, Sau M, Goldthorp W, Sidra L, Sau A. The use of methotrexate in ectopic pregnancy with fetal cardiac activity. *J Obstet Gynaecol* 1999;19(1):98-100

QUID EST HOC?

What is this?



Please send answers to the Editor, Morecambe Bay Medical Journal, Education Centre, RLI.

A £25 book token will be awarded for the first correct answer to be drawn at random.